

## Case Report

# Symptomatic Small Spigelian Hernia: Extraperitoneal Primary Laparoscopic Closure

Rizza V<sup>1\*</sup> and Pietroletti R<sup>2</sup>

<sup>1</sup>Department of Surgery, Maria SS dello Splendore Hospital, Italy

<sup>2</sup>Department of Coloproctology Surgery, University of L'Aquila, Val Vibrata Hospital, Italy

## Abstract

Spigelian hernia occurs through slit like defect in the anterior abdominal wall adjacent to the semilunar line. The hernia ring is a well defined defect in the transverse aponeurosis. The hernial sac, surrounded by extraperitoneal fatty tissue, is often interparietal passing through the transversus and then spreading out beneath the intact aponeurosis of the external oblique. Spigelian hernia is in itself very rare and more over it is difficult to diagnose clinically. The repair of Spigelian hernia consists of reconstructing the anterior abdominal parietal defect. The defect repair may be made with or without prosthesis. This hernia has been repaired by both conventional and laparoscopic approach. In this paper we report a case of a small symptomatic small Spigelian hernia, treated with a mini-invasive laparoscopic approach associated to the extraperitoneal closure of the hernial ring without prosthesis.

## Introduction

Spigelian hernia, or ventro-lateral hernia is a rare condition, it represents about 1%, 5% of hernia formation cases of the abdominal wall [1,2]. Spigelian hernia occurs through slit like defect in the anterior abdominal wall adjacent to the semilunar line. The hernia ring is a well defined defect in the transverse aponeurosis. The hernial sac, surrounded by extraperitoneal fatty tissue, is often interparietal passing through the transversus and then spreading out beneath the intact aponeurosis of the external oblique [1]. The line, which joins the IX rib to the pubic tubercle, defines the limit between muscular and aponeurosis portion of transversus abdominis muscle. Diagnosis often results misunderstood. The hernial sac and its content can be appreciated subcutaneously in only 2% of cases. It is estimated that about 50% of patients affected by condition have a certain diagnosis before surgery [2]. In case of uncertain imaging the laparoscopic approach is necessary to the diagnosis and to treat Spigelian hernia. We report a case of a symptomatic and small (diameter hernia ring less than 5 mm) Spigelian hernia in a 74 year old man treated with a laparoscopic approach associated to defect extraperitoneal primary closure with absorbable suture and no absorbable clips. We believe that this approach allows an early and safe discharge in case of subcentimetric Spigelian Hernia.

## Case Presentation

A 74 year old overweight Caucasian man was valued for disabling chronic pain to left abdominal flank in absence of vomit, nausea, fever, and diarrhea. There was no particular comorbidity. The abdominal

objective examination showed only small tumor to the left abdominal flank of unclear nature, aching, with a diameter inferior to 5 mm, not reducible in abdominal cavity; abdominal TC was performed without contrast medium to study the abdominal wall. The TC report was negative for abdominal hernia. In accordance with the literature we performed a laparoscopic approach with one 12 mm umbilical trocar, one 5 mm trocar in right iliac fossa and 5 mm trocar in hypogastric region. Laparoscopic exploration showed a little peritoneal depression to the anterior abdominal wall adjacent to the left semilunar line in absence of an evident hernia ring: because, during general anesthesia, the external palpation showed a small parietal defect in correspondence of peritoneal depression we laparoscopically opened the anterior peritoneum near the presumptive defect. The opened peritoneum showed extraperitoneal and interparietal fatty tissue passing through the transversus and spreading out beneath the intact aponeurosis of the external oblique (Figure 1). The hernia ring had a diameter less than 5 mm in the transverse aponeurosis (Figure 2). Reduced the fatty tissue in abdominal cavity, we sutured the hernia ring by absorbable 2/0 suture anchored with no absorbable clip. (Figure 3) The fatty tissue extraperitoneally repositioned allowed the closure of the peritoneum with absorbable 3/0 suture anchored with no absorbable clip (Figures 4 and 5). No drain has been placed. The outcome was excellent with early disappearance of pain from the first postoperative day and an early resumption of physical activity in absence of signs of recurrence in the short and medium term.

## Discussion

Adriaan van der Spiegel described the semilunar line (linea Spigeli) in 1645 but Josef Klinkosch in 1764 defined the Spigelian hernia as a defect in the semilunar line. Defects in the aponeurosis of transverse abdominal muscle have been considered as the principal etiologic factor. The aponeurosis of transverse abdominal muscle is limited by the linea semilunaris laterally and the lateral edge of the rectus muscle medially [3]. This type of hernia represents about 1%, 5% (0%, 1%-2%) of hernia formation cases of the abdominal wall and can be a congenital or acquired defect in the spigelian aponeurosis [2,4]. It is much less common than inguinal or femoral hernias. Pediatric cases, especially neonates and infants, are mostly congenital, embryologically, spigelian hernias may represent the clinical outcome

**Citation:** Rizza V, Pietroletti R. Symptomatic Small Spigelian Hernia: Extraperitoneal Primary Laparoscopic Closure. *Am J Surg Case Rep.* 2022;3(4):1042.

**Copyright:** © 2022 Rizza Vinicio

**Publisher Name:** Medtext Publications LLC

**Manuscript compiled:** Nov 25<sup>th</sup>, 2022

**\*Corresponding author:** Rizza Vinicio, General Surgery Unit, Maria SS dello Splendore Hospital, Giulianova, ASL Teramo (Te), Italy, E-mail: vinicior1979@gmail.com

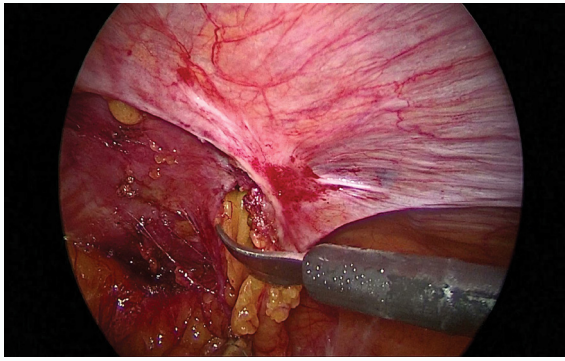


Figure 1: Extraperitoneal fatty tissue.

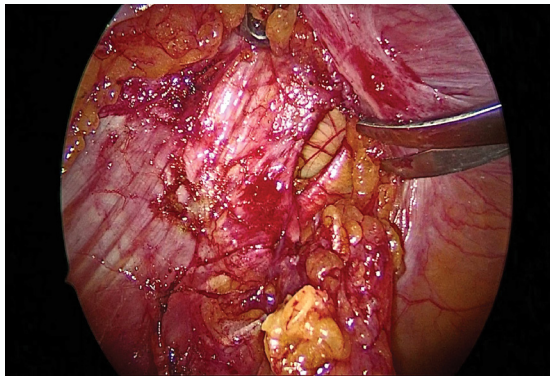


Figure 2: Spigelian hernia ring.

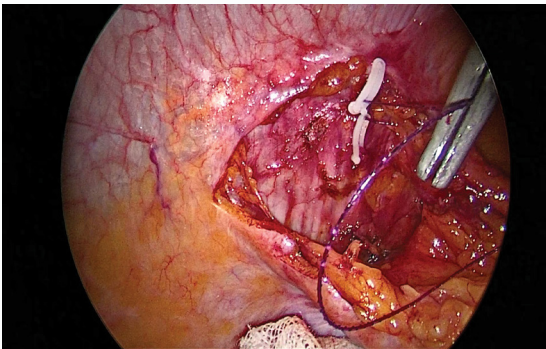


Figure 3: Extraperitoneal defect suture.

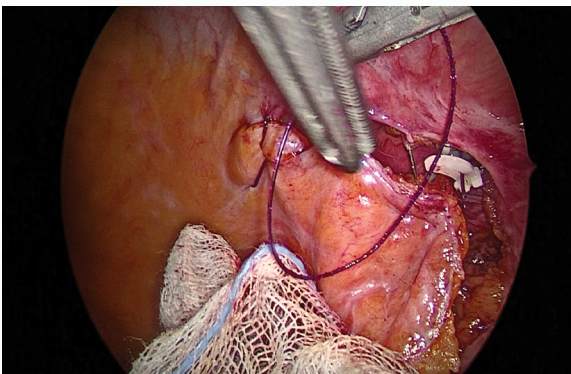


Figure 4: Peritoneal suture.

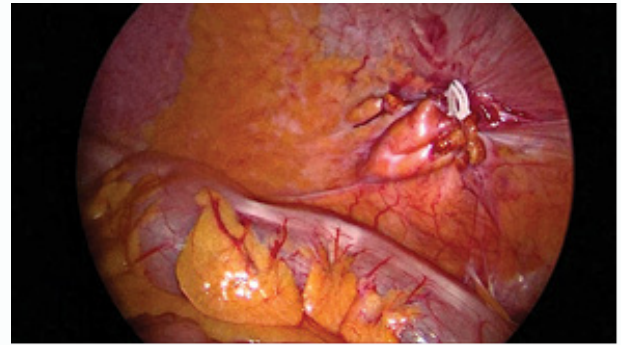


Figure 5: Intraperitoneal outcome.

of weak areas in the continuation of aponeurosis of layered abdominal muscles as they develop separately in the mesenchyme of the somatopleure, originating from the invading and fusing myotomes. In the adult this defect is often associated to the obesity [3]. The hernia appears to peak in the fifth decade of life and more common in the women [4]. Risk factor for a spigelian hernia include long standing medical conditions that increase abdominal pressure like chronic cough, frequently straining to have a bowel movement, trauma to the abdomen, frequently straining to lift heavy objects, liver problems, being overweight/obesity, being pregnant, surgical iatrogenic injury to the abdomen [5]. Spigelian hernias usually have the omentum, or bowel, passing through a narrow opening. The principal symptom is the abdominal pain. The Spigelina hernia complications may be incarceration, obstruction, strangulation. The incarceration happens when part of the bowel or abdominal tissue gets trapped in the hernia's sac. Incarceration occurs in 27% of spigelian hernia cases. Obstructions consist in the loop sticking of the intestine gets in a narrow opening, the contents cannot move ahead. Hernia's strangulation occurs when bowel gets stuck through a narrow opening and the blood supply is blocked; it is a dangerous condition because it could cause necrosis of the herniated tissue. Several different surgical strategies have been adopted for Spigelian hernia repair: open approach with or not mesh placement, laparoscopic approaches like primary defect closure, IPOM (intraperitoneal onlay method), TAPP (transabdominal preperitoneal mesh placement), and TEP (totally extraperitoneal mesh placement). The role of laparoscopic approach is very important to evaluate bilaterally the abdominal wall conditions [6,7]. In literature the follow up is poorly but is clear that the laparoscopic approach with mesh placement is a safe procedure. The literature not clearly reported the description of small Spigelian hernia treatment with a diameter less than 5 mm; so we reported a transabdominal extraperitoneal laparoscopic primary defect closure in a case of sintomatic Spigelian hernia with a diameter less than 5 mm. In this case Spigelian hernia had the preperitoneal fatty tissue passing through the narrow opening. We decided to use primary defect closure because the defect had a diameter inferior to the trocar access (less than 5 mm) and because only aponeurosis of the transverse abdominal muscle was injured: all other muscular structures of the abdominal wall were intact. We performed the suture of the hernia ring by absorbable 2/0 suture anchored with no absorbable clip; the fatty tissue extraperitoneally placement allowed the closure of the peritoneum with absorbable 3/0 suture anchored with no absorbable clip. This technique allowed a minimal postoperatorio risk with early disappearance of pain, an early and safe discharge.

## Conclusion

Several recent technical innovations have allowed us to repair the Spigelian hernia. As shown in this case report, our technique was performed successfully, highlighting its safety and feasibility.

## References

1. Mittal T, Kumar V, Khullar R, Sharma A, Soni V, Bajjal M, et al. Diagnosis and management of Spigelian hernia: a review of literature and our experience. *J Minim Access Surg.* 2008;4(4):95-8.
2. Zennaro F, Tosi D, Orio A, Morelli C, Chella B. [Spigelio's hernia. Anatomico-clinical considerations and description of 5 clinical cases]. *Ann Ital Chir.* 2003;74(2):165-8.
3. Skandalakis PN, Zoras O, Skandalakis JE, Mirilas P. Spigelian hernia: surgical anatomy, embryology, and technique of repair. *Am surg.* 2006;72(1):42-8.
4. Ruiz LA, Prats IA, Liendo PM, Noboa FN, Calero AM. Spigelian hernia. Personal experience and review of the literature. *Rev esp Enferm Dig.* 2010;102(10):583-6.
5. Shih YC, Sun HP. Spigelian hernia showing itself as left lower abdominal mass. *Formosa J Surg.* 2014;47(2):78-81.
6. Majeski J. Open and laparoscopic repair of Spigelian hernia. *Int Sur.* 2009;94(4):365-9.
7. Barnes TG, McWhinnie DL. Laparoscopic Spigelian Hernia Repair: A Systematic Review. *Surg Laparosc Endosc Percutan Tech.* 2016;26(4):265-70.